

Antebrachial Angular Limb Deformity in the Canine

Lauren A. Emery

Advisor: Ryan Butler, DVM, MS, Diplomate ACVS

July 1, 2016

Introduction

Antebrachial angular limb deformities originate as a common complication of ulnar and radial physal fractures.⁷ If possible, minimizing or preventing angular limb deformities with surgery is ideal.¹ Any breed of dog can develop angular limb deformities secondary to physal damage and premature closure. However, chondrodystrophic breeds such as Dachshunds, Basset Hounds, Beagles, and English Bulldogs, among others, are over-represented due to their limb conformation predisposing to antebrachial deformities.⁹ Severity of the deformity dictates whether medical or surgical management is necessary. It has been found that dogs can compensate for up to a 15% length deficit.³ Diagnostic imaging options include radiographs and computed tomography (CT). If surgical intervention is sought, at least one corrective osteotomy is required and is typically stabilized with either plate and screws or an external skeletal fixator (ESF).¹ It is important to keep in mind that treatment depends on the amount of growth remaining and location of the premature closure.¹

History and Presentation

The typical signalment for angular limb deformity patients is a young, healthy puppy. Cats seldomly present with limb deformities.⁷ For some patients, it may be difficult to determine what caused the angular limb deformity. Possibilities include congenital malformation, malunion, nutritional imbalances, physal trauma, and radiation exposure; all of which lead to growth plate retardation.⁹ Majority of studies show that there is a misalignment of the radius as a result of growth disturbances in canids.⁸ Distal or proximal radial physes as well as the distal ulnar physis can prematurely close. Seventy-five percent of growth disturbances in the canine thoracic limb are due to a change in the distal ulnar physis. Cessation of ulnar growth results in radial procurvatum, carpal valgus, limb shortening, and/or external rotation.⁵ Depending on the

amount of growth remaining in the contralateral limb, there may be a great difference in forelimb lengths. This may cause the dog to become painful if osteoarthritis develops from abnormal posture and weight bearing on the elbow and/or carpal joint(s).⁵

Pathophysiology

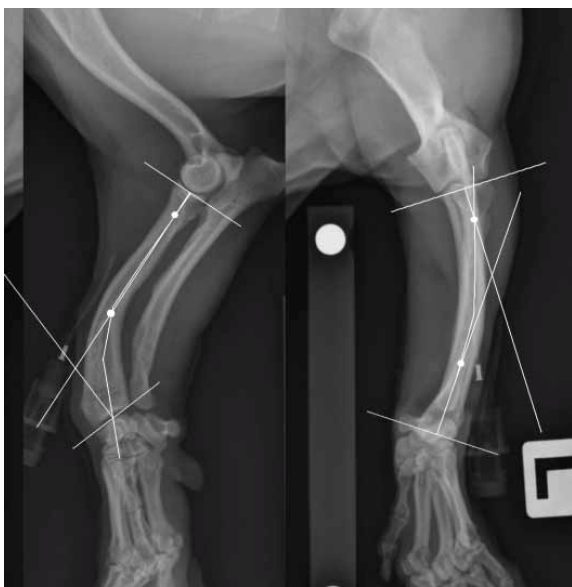
Various deformities occur in the antebrachium depending on which physis is disrupted and if it is symmetric or asymmetric. The lateral aspect of the distal radial physis is often affected and causes carpal valgus, elbow joint subluxation, and distal subluxation of the radial head.¹ Most commonly reported is early closure of the distal ulnar physis.¹ This is due to the conical shape of the distal ulna. When it undergoes trauma, a Salter-Harris type V crushing injury causes the premature closure.⁷ This closure and subsequent continued radial growth results in carpal valgus, radial procurvatum, radial shortening, elbow joint subluxation, and external rotation of the distal forelimb. All of the previously mentioned changes ultimately lead to secondary degenerative joint disease.¹ Symmetric premature closure of the distal or proximal radial physis does not usually produce angular limb deformity; however, radial shortening with subsequent elbow incongruity may be noted.¹ Sixty percent of the growth of the radius is from the distal physis with the remainder from the proximal physis. This compares to the ulna which receives 80% of its length from the distal physis.⁷ Limb length can be greatly impacted if a dog sustains an injury to either or both of the distal physes.

Differential Diagnoses

While focus of this discussion is on premature closure of physes, consideration should be given to possible differentials for growth deformities. Associated ligaments and tendons could be contracted or lax. Poor conformation is another differential for growth deformities.⁷ A definitive diagnosis can be made following a proper physical exam and diagnostic imaging.

Diagnostics Approaches/Considerations

A thorough physical exam should be followed by an orthopedic exam with careful palpation of each of the joints. Radiographs should be taken to determine the CORA, center of rotation of angulation, which will help to identify the severity of the deformity and where a corrective osteotomy needs to be made.⁹ Radiographs of the antebrachium should include two views, craniocaudal and lateral views. If the contralateral limb is unaffected, control radiographs should be taken to determine the patient's "normal" angles for correction purposes. The craniocaudal view requires that joint orientation lines be drawn at the radiocarpal and elbow joints.² Two additional orientation lines are made 90° to the middle of the joint lines.² An orientation line is made from the proximomedial aspect of the medial coronoid process to the proximolateral aspect of the radial head to trace the limb deformity.² Normal canine antebrachia have a natural procurvatum, which necessitates taking a segmental, proximal antebrachium and distal antebrachium, lateral radiograph. Using the determined mid-diaphyseal point, joint orientation lines are again drawn with 90° intersecting orientation lines along with a third tracing the limb deformity.² Where the distal and proximal orientation lines meet the deformity tracing is where the CORA lies.²



This image shows examples of craniocaudal and lateral antebrachia radiographs with the CORAs represented by the white dots along the axes.²

Angular limb deformities can be classified as uniapical (one CORA), biapical (two CORAs), or multiapical (more than two CORAs).⁸ When totaling CORAs from both the sagittal and frontal views, it can be determined if the patient's deformity is uniplanar or multiplanar.⁸ While radiographs and measuring angles work well to correct angular limb deformities, computed tomography (CT) can be a much more valuable diagnostic tool. After completion of a CT of the affected limb, 3D, lifesize bone models can be created to practice measurements and osteotomies before surgery.⁴ This is a good time to measure implants on the bone as well. One study mentions creating a saw guide from PMMA (polymethyl methacrylate) that was then used in the planning process and cold sterilized for surgery. They also pre-contoured the plate during preparation so that it could be sterilized and ready for surgery.²

Consideration should be given to physeal closure times. This time varies by breed and size of the dog; however, most dogs grow quickly from four to six months of age and slow down around nine to ten months. Larger dogs tend to take longer to mature than smaller dogs.⁷ Since physeal closure times can vary, orthogonal radiographs can be used to determine if the physes are open or closed. During growth, until endochondral ossification is complete, the physis is radiolucent. Once the physis is closed, it appears radiodense.⁷

Treatment and Management Options

Many treatment options are used for antebrachial limb deformities in dogs, however; only some may be used for certain cases. Commonly, a closing wedge osteotomy is reduced with a T-plate for deformities of the distal radius. Special care is taken to avoid the radiocarpal joint as most of the osteotomy sites in a study by Balfour, et al were 2-3 cm from the joint space.¹ Most of the previously mentioned cases had additional external coaptation that included either a metaspint, cast, or soft padded bandage.¹ Another option for correction is by using

intraoperative alignment paired with an external skeletal fixator (ESF). An advantage to external fixators is that changes to alignment can be made progressively following surgery, which is not a possibility with plate fixation. However, external fixators require a significantly higher amount of client compliance, careful pre-operative planning, and special surgical equipment.³ If there is a reasonable amount of growth potential remaining in the ulna during a radial correction surgery, a fat graft can be added to the ulna osteotomy site.¹ Immediately post-operation, the patient should be continued on pain management and a bandage or splint should be applied. Recheck radiographs need to be performed every 4 weeks until radiographic healing is complete. Strict cage rest needs to be emphasized to the owner in order to obtain the best outcome.⁷ With all of the available options, strong consideration needs to be made to owner compliance and the location of the CORA(s).

Expected Outcome and Prognosis

Patients that underwent surgical correction of angular limb deformities using a T-plate fixation showed an average of 8 weeks for radiographic healing.¹ Similarly, patients with a double-arc external fixator can expect 9 ± 3.8 weeks as the mean radiographic union of the radius and ulna.⁵ If delayed radiographic union of the radius and ulna was evident, the external fixator remained on longer. This occurred in 5 out of 35 limbs in a study by Fitzpatrick, et al.⁵ A study using a type 1-B external fixator, found that intra-operative alignment provided a sufficient correction to angular limbs, as opposed to plating.³ In regards to joint disease, a study by Knapp, et al showed that dogs with a biapical deformity were 3.2 times more likely to have elbow joint disease present. In the same study, there is evidence that 2 CORAs in the frontal plane make elbow joint disease 3.6 times more likely.⁹ When comparing chondrodystrophic to non-chondrodystrophic breeds, they are 3.5 times more likely to have elbow joint disease.⁹

Degenerative joint disease is irreversible, however, it can be managed with joint supplements, weight management, exercise moderation, and non-steroidal anti-inflammatories.⁶

Conclusion

In conclusion, there are several forms of surgical correction to consider. When deciding between using plate fixation or external skeletal fixator, consider where the osteotomies will be located and the amount of client compliance that is required post-operation.¹ While radiographs are good for creating angles and measurements, CT is the best diagnostic tool so that all angles can be properly evaluated.⁴ Overall, majority of clients are pleased with the outcome of their dog's surgery.³

References

1. Balfour R, Boudrieau R, Gores B. T-plate fixation of distal radial closing wedge osteotomies for treatment of angular limb deformities in 18 dogs. *Veterinary Surgery: VS* [serial online]. May 2000;29(3):207-217.
2. Crosse K, Worth A. Computer-assisted surgical correction of an antebrachial deformity in a dog. *Veterinary And Comparative Orthopaedics And Traumatology : V.C.O.T* [serial online]. 2010;(5) Available from: AGRIS, Ipswich, MA. Accessed June 20, 2016.
3. Deruddere K, Snelling S. A retrospective review of antebrachial angular and rotational limb deformity correction in dogs using intraoperative alignment and type 1b external fixation. *New Zealand Veterinary Journal* [serial online]. September 2014;62(5):290-296. Available from: MEDLINE, Ipswich, MA. Accessed June 20, 2016.
4. Dismukes D, Fox D, Tomlinson J, Essman S. Use of radiographic measures and three-dimensional computed tomographic imaging in surgical correction of an antebrachial deformity in a dog. *Journal Of The American Veterinary Medical Association* [serial online]. January 2008;232(1):68-73. Available from: Academic Search Complete, Ipswich, MA. Accessed June 20, 2016.
5. Fitzpatrick N, Nikolaou C, Yeadon R, et al. The double-arch modified type-1b external skeletal fixator. Technique description and functional outcome for surgical management of canine antebrachial limb deformities. *Veterinary And Comparative Orthopaedics And Traumatology: V.C.O.T* [serial online]. 2011;24(5):374-382. Available from: MEDLINE, Ipswich, MA. Accessed June 20, 2016.
6. Fossum T. Diseases of the Joints. In: *Small Animal Surgery*. St. Louis, Mo. : Elsevier Mosby, [2013]; 2013. 34: 1215-1223.
7. Fossum T. Radial and Ulnar Growth Deformities. In: *Small Animal Surgery*. St. Louis, Mo. : Elsevier Mosby, [2013]; 2013. 33: 1154-1159.
8. Fox D, Tomlinson J, Cook J, Breshears L. Principles of Uniapical and Biapical Radial Deformity Correction Using Dome Osteotomies and the Center of Rotation of Angulation Methodology in Dogs. *Veterinary Surgery* [serial online]. 2006;(1):67. Available from: Academic OneFile, Ipswich, MA. Accessed June 20, 2016.
9. Knapp J, Tomlinson J, Fox D. Classification of Angular Limb Deformities Affecting the Canine Radius and Ulna Using the Center of Rotation of Angulation Method. *Veterinary Surgery* [serial online]. 2016;(3):295. Available from: Academic OneFile, Ipswich, MA. Accessed June 20, 2016.